Int. J. Oral Maxillofac. Surg. 2015; 44: 1547–1557
http://dx.doi.org/10.1016/j.ijom.2015.04.006, available online at http://www.sciencedirect.com

International Journal of
Oral & Maxillofacial Surgery

Clinical Paper
Clinical Pathology

Retrospective analysis of osteoradionecrosis of the mandible: proposing a novel clinical classification and staging system

Y. He, Z. Liu, Z. Tian, T. Dai, W. Qiu, Z. Zhang
Department of Oral Maxillofacial and Head and Neck Oncology, Shanghai Ninth People's Hospital Affiliated to Shanghai Jiao Tong University School of Medicine, Shanghai, China

Y. He, Z. Liu, Z. Tian, T. Dai, W. Qiu, Z. Zhang: Retrospective analysis of osteoradionecrosis of the mandible: proposing a novel clinical classification and staging system. Int. J. Oral Maxillofac. Surg. 2015; 44: 1547–1557. © 2015 International Association of Oral and Maxillofacial Surgeons. Published by Elsevier Ltd. All rights reserved.

Abstract. Osteoradionecrosis of the jaw is a common radiation-induced complication that may be observed in oral cancer patients. Several classifications and staging systems have been proposed for osteoradionecrosis of the mandible based on clinical symptoms, radiological findings, and/or the response to diverse treatments. However, none has been universally accepted because of their individual deficiencies. The aim of this study was to introduce a new clinical classification that can be applied to the treatment of osteoradionecrosis in an easier and more acceptable way, through a retrospective analysis of patients with osteoradionecrosis of the mandible. A review was conducted of 99 patients diagnosed with osteoradionecrosis of the mandible in the study institution between 2000 and 2013. A novel classification was established on the basis of bone necrosis and soft tissue defects. A new staging system with four different stages (stage 0, stage I, stage II, and stage III) is proposed. We believe that this new classification and staging system is easier and more acceptable for clinical evaluation than previous ones.

Key words: osteoradionecrosis of the mandible (ORNM); clinical classification; staging system.

Accepted for publication 14 April 2015
Available online 11 July 2015

Radiotherapy has been an indispensable primary treatment or adjuvant treatment for malignant oral and maxillofacial tumours. Although it plays an ameliorative role in local control of the tumour and in improving the survival rate, late adverse effects such as osteoradionecrosis of the jaw (ORNJ) cannot always be avoided and may have a tremendous psychological and physical impact on the patient.

Regaud first reported ORNJ in 1922,[1] and a great deal of attention has since been paid to this clinical challenge. In 1983, Marx defined ORNJ as ''an area greater than 1 cm of exposed bone in a field of irradiation that had failed to show any evidence of healing for at least six months''.[2] Since then, several different theories and definitions relating to ORNJ have been proposed by various researchers.[3,4]

Despite the lack of a standard and unified definition, ORNJ is characterized by different extents of bone necrosis combined with soft tissue defects. These

0901-5027/01201547 + 011 © 2015 International Association of Oral and Maxillofacial Surgeons. Published by Elsevier Ltd. All rights reserved.

varying degrees of bone destruction make it essential that a classification and staging system be devised to help provide a strategy for the clinical treatment of osteoradionecrosis of the mandible (ORNM).

In 1983, Marx reported the Wilford Hall hyperbaric oxygen (HBO) osteoradionecrosis protocol, consisting of three stages based on the response to HBO therapy, which was applied due to the aetiological hypothesis of 'hypoxia, hypocellularity, and hypovascularity'.[5] This classification was validated by its excellent therapeutic outcomes and wide utilization by subsequent investigators. Nevertheless, this basic grading system has its limitations, including: (1) it is not applicable in patients not receiving HBO, (2) it lacks a description of the pathophysiology of ORNM, and (3) the effect of HBO therapy is now in question.[6–9] Slightly different to Marx, Tsai et al.,[10] using a classification of four stages, categorized patients who required HBO therapy as being stage III, while various alternative treatments were needed for the other stages. This classification is also not ideal for clinical evaluation.

There are many controversies regarding the aetiology and pathophysiology of ORNJ.[11–13] In 2014, Lyons et al.[14] proposed a new classification based on the therapeutic effects of the anti-fibrotic drug pentoxifylline, which was prescribed to patients as a result of the fibro-atrophic theory that was elucidated by Delanian and Lefaix.[13] This theory has a close association with anti-fibrosis and may lose its grading efficiency when the anti-fibrotic factor is removed. Epstein et al.[4] were the only authors to elaborate their classification according to the status of ORNM progression. This was a completely new idea that was quite different from the other theories and provided an instructional way to determine when the management of ORNM should be performed. Clinically, it is difficult to judge how ORNM is progressing; the essential nature of the disease has been ignored. Some investigators established their staging systems based upon the extent of bone destruction described in the vertical direction, such as inferior mandible border involvement, inferior alveolar nerve canal involvement, and local or diffuse involvement.[15–17] These methods provided quantitative analysis for the necrotic bone, but were unsuitable for that originating from the central bone.[18]

From this review, it can be seen that these proposed classifications were available and deemed suitable for application in the investigators' own institutions, although their limitations are evident. The aim of this study was to establish a new clinical classification that divides ORNM into different stages of escalating degrees, and that can be applied to the treatment of ORNM in an easier and more acceptable way.

Patients and methods

The files of patients diagnosed with ORNM in the department of oral maxillofacial and head and neck oncology of the study institution during the period 2000–2013 were collected retrospectively. In this study, ORNM was defined as radiological evidence of bone necrosis within the irradiated region of the mandible, as proposed by Store and Boysen.[19] To be included in this classification, patients had to fulfil the following criteria: (1) diagnosed with osteoradionecrosis of the mandible without primary tumour recurrence; (2) received single, prior radiation in the study institution; (3) had no severe systemic comorbidities (e.g., coronary heart disease, mental illness, or cachexia); (4) received subsequent treatments in the study institution (eliminating the interference of other organizations); and (5) had complete treatment and follow-up information.

Patients with different malignant tumours of the head and neck region were treated with radiotherapy in the study institution. The duration of follow-up covered the period from the completion of radiotherapy to the day of analysis, divided into time intervals of 3 months. As patients developed ORNM during the research period, the specific sites affected were recorded. The clinical manifestations were also summarized, including spontaneous pain (mild: intermittent pain that patients could endure; moderate: persistent pain that patients could bear; severe: pain that could not be tolerated), bone exposure, skin fistula, limitation in mouth opening, numbness, and pathological fracture. The maximal diameter of the bone lesion and the status of the pathological fracture were assessed by computed tomography (CT), i.e., the maximal diameter was determined by the maximum length acquired from the CT images. The buccolingual and anteroposterior diameters were measured on the transverse section, and the vertical diameter was measured on the coronal plane. Through sliding the bone window in the CT software, it was possible to determine the maximal length in different directions; the maximal length was then selected.

The treatment records were carefully collected, including information on conservative therapy (e.g., antibiotics, oral hygiene control, and immunity enhancement), sequestrectomy, and segmental mandibulectomy with or without vascularized tissue reconstruction. The treatment outcomes were recorded as 'resolved', 'improved', 'stable', or 'progressed'. 'Resolved' relates to the status in which the patient is asymptomatic without progression and has relatively good function. 'Improved' relates to the status in which the patient has relief from their symptoms and where the necrotic lesion is noted on radiography to be decreased. 'Stable' signifies that the disease has neither progressed nor improved. 'Progressed' indicates deterioration in the condition of the patient.

Based on these clinical features of ORNM and previous classification schemes, a new classification system was developed that classifies all patients into different groups demonstrating varying disease severity. The clinical features, corresponding therapies, and outcomes of patients in the distinct stages are described below.

Results

Demographic and clinical characteristics

A total of 120 patients (maxilla $n = 11$, mandible $n = 109$) suffering from ORNJ were registered in the electronic database of the study institution. Ten ORNM patients were excluded as they did not fulfil the study inclusion criteria, hence 99 patients with ORNM (male $n = 72$, female $n = 27$) were ultimately analysed in this study. The age at diagnosis of these 99 patients ranged from 26 to 78 years, with a mean and median age of 54.5 and 55 years, respectively. The primary malignant tumours are listed in Table 1.

The X-ray doses resulting in ORNM were within the range of 60 to 74 Gy, with a mean and median dose of 65.5 and 68 Gy, respectively. All patients underwent external beam irradiation with Cobalt-60 irradiation (25.8%) or with a linear accelerator (74.2%). Most of the ORNM ($n = 55$, 55.6%) had occurred within the first 12 months of the post-irradiation period; 27 patients (27.3%) were diagnosed at 12–60 months post-irradiation and 17 patients (17.2%) at 5 years after receiving the radiation therapy (Table 2). ORNM in the mandibular body without ramus involvement was observed in 55 patients (55.6%), involvement of the ramus alone occurred in seven patients (7.1%), and involvement of the mandibular body combined with the ramus was observed in 37 patients (37.4%).

Table 1. Primary tumour locations in the head and neck region of patients who underwent radiotherapy.

Locations	No. of cases ($N = 99$)	Percentage (%)
Oral cavity malignant tumours		
Tongue	24	24.2
Floor of the mouth	11	11.1
Palate	3	3.0
Buccal area	9	9.1
Mandible	5	5.1
Gingiva	8	8.1
Pharynx malignant tumours		
Oropharynx	8	8.1
Nasopharynx	27	27.3
Salivary gland malignant tumours		
Parotid gland	1	1.0
Submandibular gland	3	3.0

Table 2. The time of occurrence of osteoradionecrosis of the mandible following radiotherapy.

Time (months)	No. of cases ($N = 99$)	Percentage (%)
≤12		
≤3	23	23.2
4–6	12	12.1
7–9	5	5.1
10–12	15	15.2
13–24	12	12.1
25–36	8	8.1
37–48	4	4.0
49–60	3	3.0
>60	17	17.2

Radiographic examination was an indispensable approach to evaluating the mineralization changes and even the formation of necrotic bone or further fracture of the mandible. No distinct changes were found on radiography in eight patients (8.1%) who complained of spontaneous bony pain (mild $n = 5$, moderate $n = 3$). Ninety-one patients (91.9%) were found to have necrotic bone – 14 (14.1%) with a maximal diameter <2 cm and 65 (65.7%) with a maximal diameter >2 cm; pathological fracture was observed in 12 patients (12.1%) (Table 3).

Bone exposure and pathological fracture were typical features of ORNM and these symptoms were found in 65 (65.7%) and 12 patients (12.1%), respectively. In this study, bone exposure was not defined as a condition in which fractured bone was exposed to the oral cavity; this condition was instead assigned to the category of pathological fracture. Radiographic changes seemed not to be associated with the status of bone exposure in the oral cavity. Two patients without distinct changes on radiography had exposed bone; the vitality of such bone should be evaluated further by bone dynamic testing. In contrast, 16 patients with evident bone alterations (except for bone fracture) had an intact mucosa covering the underlying necrotic bone. More surprisingly, one patient with a pathological fracture had an intact covering mucosa.

Fifty-five patients (55.6%) developed skin fistulas, which indicated that a connection existed between the oral cavity and the maxillofacial region. This soft tissue disease played an important role in the selection of various reconstructive methods. There was also no correlation between external skin fistulas and bone exposure, as evidenced by six patients with necrotic bone that was not exposed to the oral cavity who were discovered to have skin fistulas. Seventy-seven patients (77.8%) suffered from spontaneous pain (mild $n = 26$, moderate $n = 31$, severe $n = 20$). The majority of the patients ($n = 59$, 59.6%) had a limitation of mouth opening, to varying extents (Table 3).

New classification and staging system

A summary of the previous classifications and staging systems for ORNM is shown in Table 4. The proposed new classification and staging system, based upon the retrospective study of 99 ORNM patients and the review of the previous classification methods, is shown in Tables 5 and 6;

Table 3. Clinical and radiographic characteristics of the study population and their distribution in the different stages.

Variables	No. of cases, n (%)	Stage 0	Stage I	Stage II	Stage III
Clinical manifestations					
Bone exposure	65 (65.7)	2	8	55	-
Pathological fracture	12 (12.2)	0	0	0	12
Skin fistula	55 (55.6)	0	2	43	10
Spontaneous pain					
No pain	22 (22.2)	0	6	16	0
Mild	26 (26.3)	5	6	14	1
Moderate	31 (31.3)	3	2	23	3
Severe	20 (20.2)	0	0	12	8
Numbness	13 (13.1)	0	1	3	9
Mouth opening limitation					
Mild	9 (9.1)	0	2	7	0
Moderate	25 (25.3)	0	0	23	2
Severe	18 (18.2)	0	0	13	5
Trismus	7 (7.1)	0	0	2	5
Radiographic findings					
No distinct change	8 (8.1)	8	0	0	0
Maximal diameter <2 cm	14 (14.1)	0	14	0	0
Maximal diameter >2 cm	65 (65.7)	0	0	65	0
Pathological fracture	12 (12.1)	0	0	0	12
Total number	99	8	14	65	12

a specific explanation of each stage is given below.

Stage 0

- B0S0: No evident signs or only osteolytic images on radiography; however, the patient suffers from typical ORNM-related symptoms (bone exposure or pain).

Stage I

- B1S0: The maximal diameter of the lesion on radiography is <2 cm and there is no mucosa or skin defect.
- B1S1: The maximal diameter of the lesion on radiography is <2 cm and there is an intraoral mucosa defect or external skin fistula alone.
- B1S2: The maximal diameter of the lesion on radiography is <2 cm and there is a through-and-through defect (Fig. 1).

Stage II

- B2S0: The maximal diameter of the lesion on radiography is >2 cm and there is no mucosa or skin defect (Fig. 2).
- B2S1: The maximal diameter of the lesion on radiography is >2 cm and there is an intraoral mucosa defect or external skin fistula alone.
- B2S2: The maximal diameter of the lesion on radiography is >2 cm and there is a through-and-through defect (Fig. 3).

Stage III

- B3S0: A pathological fracture is identified on radiography and there is no mucosa or skin defect (Fig. 4).
- B3S1: A pathological fracture is identified on radiography and there is an intraoral mucosa defect or external skin fistula alone.
- B3S2: A pathological fracture is identified on radiography and there is a through-and-through defect (Fig. 5).

Distribution of patients under the new staging system

The clinical and radiographic characteristics of patients in the different stages are shown in Table 3; their treatments and outcomes according to the various stages are shown in Table 7.

Eight patients were defined as stage 0, and all received conservative therapy with different outcomes (resolved $n = 5$, stable $n = 1$, progressed $n = 2$). Fourteen patients were classified as stage I; all of these patients underwent sequestrectomy. The outcome was 'resolved' for nine patients (64.3%), and two progressed to stage II. The majority of the patients were categorized as stage II ($n = 65$, 65.6%), and all of these patients underwent surgical resection (marginal $n = 9$, segmental $n = 56$). Reconstruction was performed in 47 patients (72.3%), with 17 receiving a bone flap restoration (fibula $n = 15$, iliac bone $n = 2$) and the remaining 30 patients reconstructed with only a soft tissue flap (pectoralis major flap $n = 20$, anterolateral thigh flap $n = 4$, latissimus dorsi flap $n = 3$, forearm flap $n = 3$). Nine patients who underwent marginal resection were not reconstructed and the remaining nine patients were not suitable for microvascular surgery. For stage II, the total 'resolved' rate was 72.3%. Stage III indicates the most severe degree of ORNM, and this terrible condition was seen in 12 patients. Segmental resection combined with vascularized flap reconstruction (osteocutaneous flap: $n = 4$; soft tissue flap: $n = 6$) was used in most of these cases ($n = 10$, 83.3%); the remaining two patients underwent resection only without reconstruction. The majority of stage III patients ($n = 8$, 66.7%) achieved an excellent outcome.

Discussion

ORNJ is a radiation-induced complication that is often observed in the oral maxillofacial and head and neck oncology department. This adverse effect may not occur in every irradiated patient because of the different sensitivities of tissue and bone upon exposure, and this could explain the lack of a reported association between the radiation dose and the severity of ORNJ.[19] In past decades, ORN was defined as the exposure of necrotic bone in the irradiated field that fails to heal spontaneously.[2,4,5,11,15–17] However, previous definitions omitted the special condition of the appearance of necrotic bone (even to the extent of fracture) on radiology in the presence of intact skin and mucosa.[20] Bone necrosis originating from the central bone makes the presentation of full mucosal coverage possible.[18] In 2000, Store and Boysen[19] also found that not all ORN cases involved exposed bone, and they proposed a novel concept of ORN: ''Radiological evidence of bone necrosis within the radiation field, where tumour recurrence has been excluded''. In the present study, 16 patients with evident bone alterations had an intact mucosa covering the underlying necrotic bone. Hence the definition of ORN without the precondition of bone exposure was formulated.

The presentation of maxillary ORN is less common than that of the mandible. Only a few investigators have made an attempt at proposing a clinical classification for maxillary ORN.[21,22] Compared to mandibular ORN, maxillary ORN has a better clinical course because of the anatomical features, small bone size, and good aeration of the maxilla. For this reason, conservative treatment and sequestrectomy may be sufficient, even for advanced lesions.[21] Nabil and Ramli[22] proposed a staging system (based on the classification presented in the study by Schwartz and Kagan[15]) that was suitable for both jaws when the maxillary antrum is involved. In our opinion, the differences in anatomical structure, bone density, and blood supply between the mandible and maxilla make this method of merging together the characteristics of ORN in these two areas unsuitable. Furthermore, a difference in the incidence and clinical symptoms between mandibular and maxillary ORN has been found.[23] In this study, a novel classification of mandibular ORN is proposed.

Several hypotheses have been established to explain the aetiology and pathogenesis of ORNJ, the most accepted being the 'hypoxia, hypocellularity, and hypovascularity' theory introduced by Marx,[2] followed by the fibroatrophy theory of Delanian and Lefaix.[13] Despite the existence of these scientific hypotheses, the actual mechanism of ORNJ remains unclear. Patients with different degrees of ORNJ may present with varying symptoms and radiological findings.[4,15] How to merge these clinical features together perfectly and thus establish an acceptable evaluation of the severity of disease is a challenge for surgeons in the process of clinical treatment and those involved in research. For this reason, a suitable classification should be well formulated to provide evidence-based guidelines or unified criteria for the clinical surgeon to manage ORNJ, both for treatment and research purposes.

Several staging systems have been proposed by investigators based upon their experience of managing ORNM in their respective institutions.[3–5,10,14–17,19,24–26] Controversy still exists about whether the classification should depend on the response to treatment. Marx[5] suggested that surgery and HBO therapy should be the primary treatments for ORNM, and Marx's staging system was based on the response to HBO. As expected, this classification was suitable for that particular institution, as evidenced by the high rate of resolution within the three stages. Similarly, Lyons et al.[14] associated their stages with the application of an anti-fibrotic drug, and the appropriateness and validity

Table 4. Review of previous classification methods and staging systems for osteoradionecrosis of the mandible.

Investigators	Location	No. of patients	Grading systems
Marx[5] 1983	Mandible	58	Grade I: 30 dives of HBO was used to attain mucosa recovery Grade II: Grade I non-responders who needed a transoral alveolar sequestrectomy Grade III: Grade II non-responders; a bone resection was needed Grade IV: An additional 30 dives of HBO was given to patients who needed a bone graft
Coffin[26] 1983	Mandible	22	Minor: Small sequesters that may separate spontaneously over several weeks Major: Bone necrosis extending to the entire thickness of the jaw; pathological fracture sometimes present
Morton[3] 1986	Mandible	39	Minor: Bone exposure with ulceration and a history of spontaneously resolving bony spicules Moderate: Small sequester limited in nature and resolving spontaneously Major: Large area of exposed bone and sequester; bone fracture and fistula
Epstein et al.[4] 1987	Mandible	26	Stage I: Resolved/healed, with or without pathological fracture Stage II: Chronic/persistent non-aggressive, with or without pathological fracture Stage III: Active/progressive, with or without pathological fracture
Glanzmann and Grätz[25] 1995	Mandible	189	Stage 1: Bone exposure without signs of infection and persisting for at least 3 months Stage 2: Bone exposure with infection or sequester and without the signs of stage 3–5 Stage 3: Bone necrosis treated with mandibular resection with a satisfactory result Stage 4: Bone necrosis with persisting problems despite mandibular resection Stage 5: Death due to ORNJ
Clayman[24] 1997	Mandible	Undefined	Type I: Presenting with bone lysis under intact gingiva or mucosa Type II: Bone exposure with secondary contamination; an aggressive form
Store and Boysen[19] 2000	Mandible	73	Stage 0: Mucosa defect only Stage I: Radiological evidence of necrotic bone with intact mucosa Stage II: Positive radiographic findings with denuded bone intraorally Stage III: Exposure of the necrotic bone; skin fistula and infection
Schwartz and Kagan[15] 2002	Mandible	Undefined	Stage I: Superficial involvement of the mandible only Stage II: Localized involvement of the mandible, with or without soft tissue necrosis Stage III: Diffuse involvement of the mandible, with or without soft tissue necrosis
Notani et al.[17] 2003	Mandible	87	Stage I: ORN confined to alveolar bone Stage II: ORN limited to the alveolar bone and/or above the level of the inferior alveolar canal Stage III: ORN under the lower part of the inferior alveolar canal, with fistula or bone fracture
Tsai et al.[10] 2013	Mandible	30	Stage I: Minimal bone exposure with conservative management only Stage II: Minor debridement required Stage III: HBO needed Stage IV: Major surgery needed
Karagozoglu et al.[16] 2014	Mandible	31	Stage 0: Bone exposure more than 1 month; no distinct changes on imaging Stage I: Bone exposure with no distinct changes on imaging, with or without symptoms Stage II: Bone exposure with distinct changes on imaging, with no involvement of the lower mandible border Stage III: Necrotic bone involving the lower border of the mandible
Lyons et al.[14] 2014	Mandible	85	Stage 1: <2.5 cm length of bone affected; asymptomatic Stage 2: >2.5 cm length of bone affected; involving fracture or the inferior dental nerve Stage 3: >2.5 cm length of bone affected; symptomatic, with no other features Stage 4: >2.5 cm length of bone affected; bone fracture and involving inferior dental nerve or fistula

HBO, hyperbaric oxygen therapy; ORNJ, osteoradionecrosis of the jaw; ORN, osteoradionecrosis.

Table 5. New clinical classification of osteoradionecrosis of the mandible (ORNM).

Bone/soft tissue		Classification
Bone necrosis (B)	B0:	No distinct changes or just osteolytic images on radiography, but patients suffering from typical ORNM-related symptoms (bone exposure or pain)
	B1:	Maximal diameter of the lesion on radiography <2.0 cm
	B2:	Maximal diameter of the lesion on radiography ≥2.0 cm
	B3:	Pathological fracture
Soft tissue defect (S)	S0:	Mucosal and skin integrity
	S1:	Intraoral mucosal defect or external skin fistula
	S2:	Intraoral mucosal and external skin defect; through-and-through defect

Table 6. Clinical staging system and corresponding treatments.

Stage	B/S constitution	Treatments
Stage 0	B0S0	Conservative therapy
Stage I	B1S0, B1S1, B1S2	Sequestrectomy and primary closure
Stage II	B2S0, B2S1, B2S2	Marginal resection without reconstruction, or segmental resection combined with osteocutaneous flap reconstruction; an additional soft tissue flap should be used in patients with an orocutaneous fistula
Stage III	B3S0, B3S1, B3S2	Segmental resection combined with osteocutaneous flap reconstruction; an additional soft tissue flap should be used in patients with an orocutaneous fistula

B, bone necrosis; S, soft tissue defect.

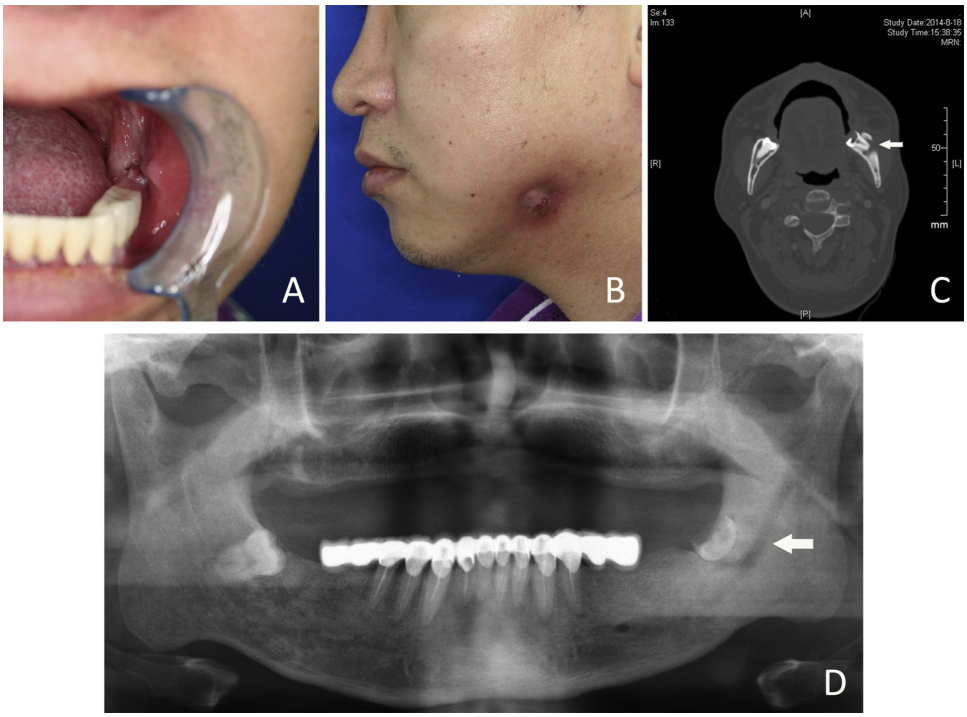

Fig. 1. Stage I patient (B1S2). (A) Bone exposure in the left retromolar area; (B) external skin fistula in the left submandibular area; (C) the necrotic lesion (<2 cm) on a transverse CT image; (D) necrotic lesion on a panoramic image.

of their method was proven by the outcomes they observed after corresponding treatments were given at different stages. However, these classifications cannot be applied to patients who have not received previous HBO therapy or an anti-fibrotic drug. Store and Boysen[19] maintained that the diagnosis of ORNM, which presents with the natural characteristics of the disease, should be made prior to treatment initiation. Most investigators have proposed staging systems based upon the clinical features of ORNM.[3,4,15–17,24] We believe that these methods are more appropriate for the pre-surgical diagnosis and evaluation of ORNM. For these classifications, the associations of stages with the corresponding treatments may not be as strong as those outlined in the studies of Marx[5] and Lyons et al.[14] There are two explanations that may account for this phenomenon, namely the selection of suitable treatments and the inhomogeneity of therapeutic effects. Hutchinson[27]

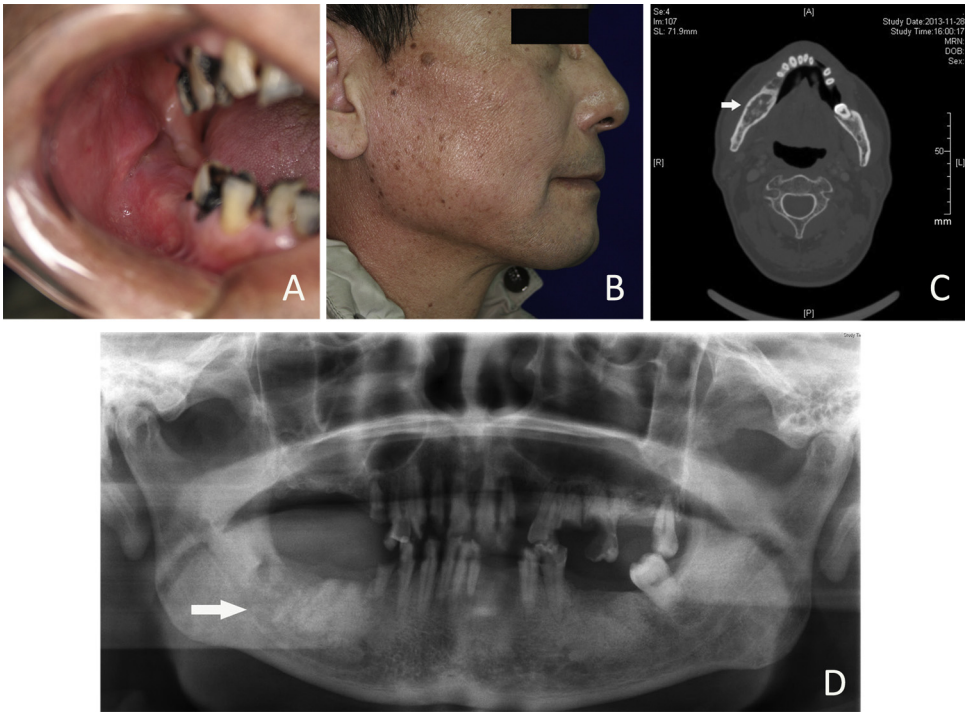

Fig. 2. Stage II patient (B2S0). (A) Intact mucosa coverage of a necrotic lesion; (B) intact skin in the right submandibular area; (C) the necrotic lesion (>2 cm) on a transverse CT image; (D) necrotic lesion on a panoramic image.

suggested that the staging system or classification should cover the following principles: (1) the degree of disease severity should be evaluated quantitatively and qualitatively; (2) the effect of therapy should be predicted; (3) the hazard should be estimated; (4) risk factors should be predicted more confidentially; (5) comparison of different treatments should be provided; and (6) the necrotic bone and subsequent treatment required should be assessed.

The new staging system presented here was established on the basis of real presentations of disease and radiological

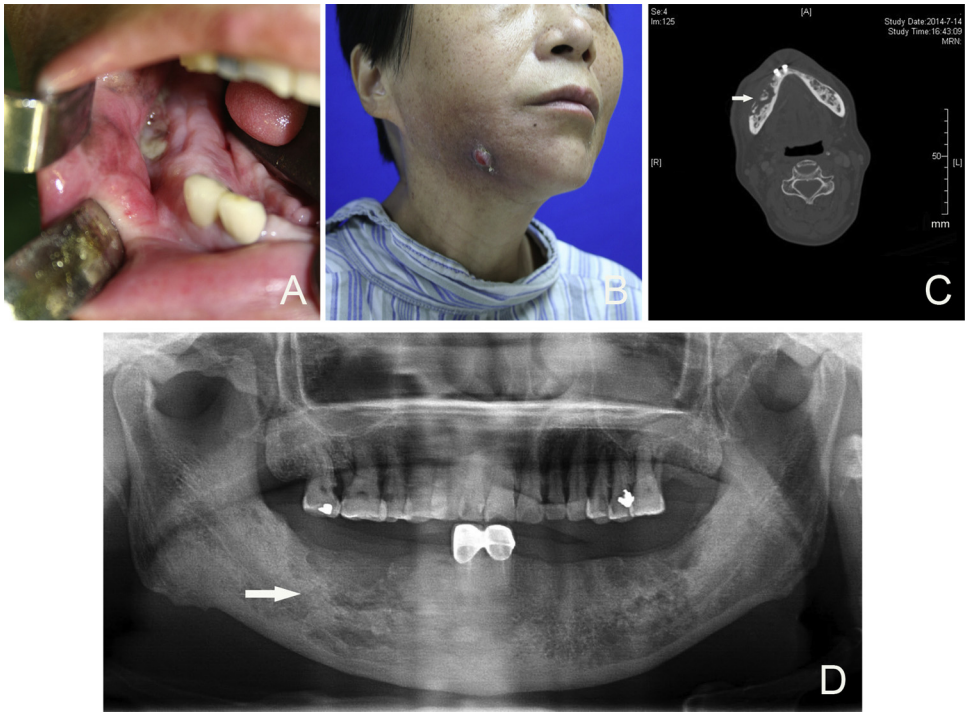

Fig. 3. Stage II patient (B2S2). (A) Bone exposure in the right retromolar area; (B) external skin fistula in the right submandibular area; (C) the necrotic lesion (>2 cm) and discontinuity of the buccal cortex on a transverse CT image; (D) necrotic lesion on a panoramic image.

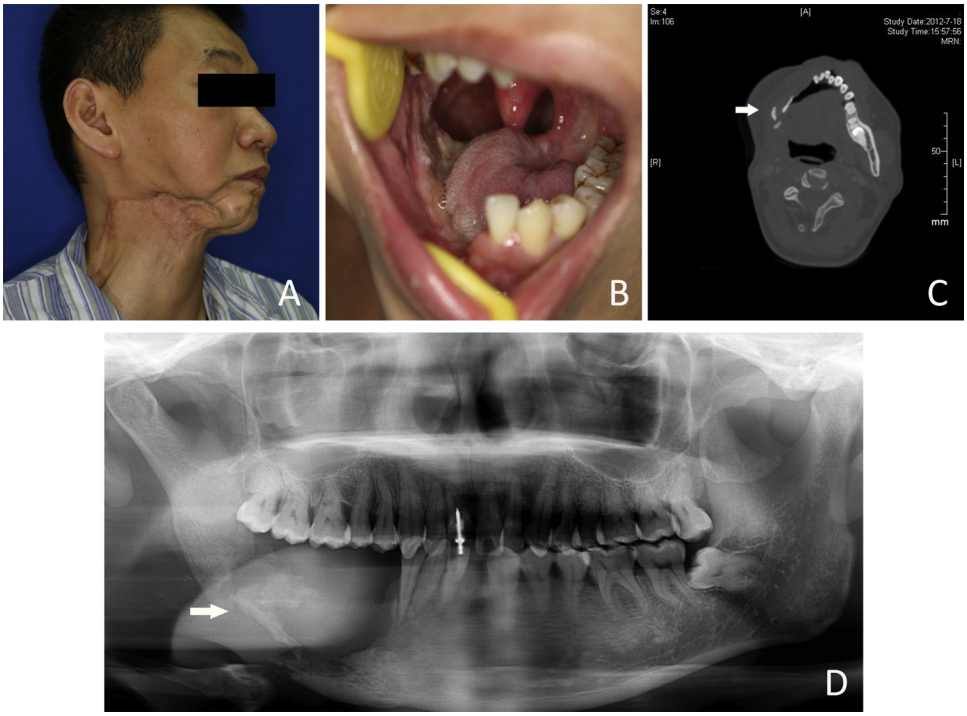

Fig. 4. Stage III patient (B3S0). (A) Intact skin in the right submandibular area; (B) intact mucosa coverage of a necrotic lesion; (C) the necrotic lesion with pathological fracture on a transverse CT image; (D) necrotic lesion with pathological fracture on a panoramic image.

findings. The best way to evaluate the degree of severity of ORNM is by measurement of necrotic bone formation.[12] Panoramic images may be used to approximate the area of the necrotic lesion. However, it is very difficult to estimate the sequester size on such planar images because of the irregularity of the lesion and the indistinct boundary between normal and necrotic bone. The same limitation exists for CT imaging. Although three-dimensional reconstructions can be

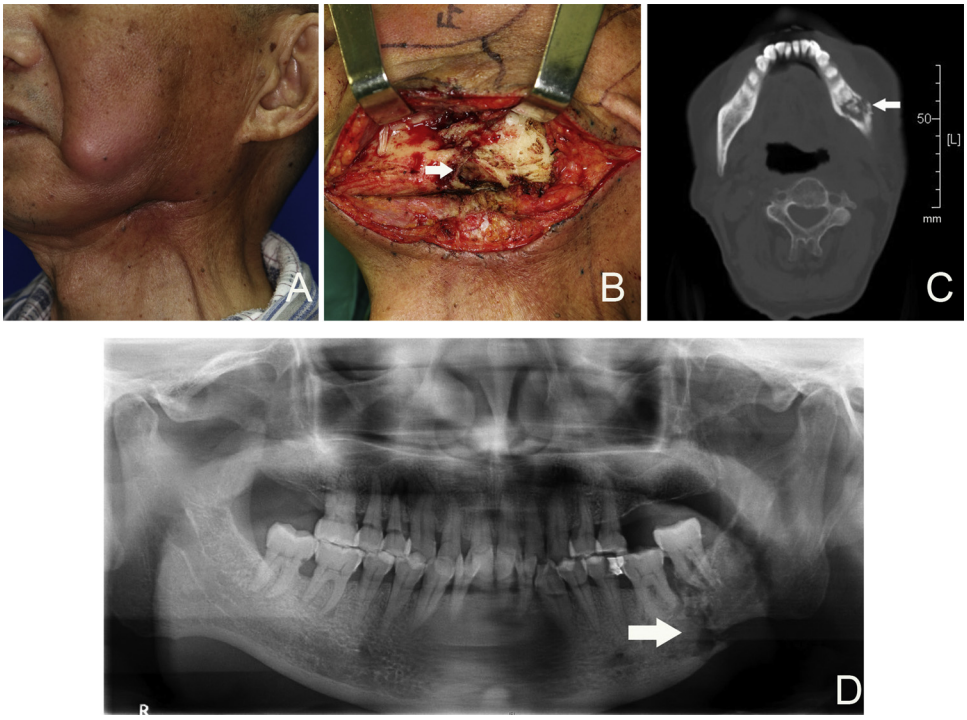

Fig. 5. Stage III patient (B3S2). (A) External skin fistula in the left submandibular area; (B) pathological fracture observed during surgery; (C) the necrotic lesion (pathological fracture) on a transverse CT image; (D) pathological fracture on a panoramic image.

Table 7. The outcomes of patients with different stages following treatment.

Stage	No.	Treatments					Outcomes			
		Conservative	Surgery				Resolved	Improved	Stable	Progressed
			Sequestrectomy	Resection with bone flap	Resection with soft tissue flap	Resection only				
0	8	8	0	0	0	0	5	0	1	2
I	14	0	14	0	0	0	9	1	2	2
II	65	0	0	17[a]	30[b]	18	47	4	6	8
III	12	0	0	4[c]	6[d]	2	8	0	3	1
Total	99	8	14	21	36	20	69	5	12	13

[a] Fibula ($n = 15$) and iliac crest ($n = 2$).
[b] Pectoralis major flap ($n = 20$), anterolateral thigh flap ($n = 4$), latissimus dorsi flap ($n = 3$), and forearm flap ($n = 3$).
[c] Fibula ($n = 3$) and iliac crest ($n = 1$).
[d] Anterolateral thigh flap ($n = 1$), sternocleidomastoid flap ($n = 1$), palatal flap ($n = 1$), and pectoralis major flap ($n = 3$).

produced to calculate the volume of the necrotic lesion (which is the most accurate means to estimate the degree of severity of ORNM), this method is still not readily available for clinical evaluation, and the specific analysis software has not been used widely. This may be the reason why Lyons et al.[14] selected the length of bone affected (with a cut-off of 2.5 cm) to make a quantitative assessment of the necrotic lesions. In the current classification, the maximal diameter is used, which is more appropriate than the length. The selected cut-off point of 2 cm is based on the different treatment regimens applied. For example, for patients with necrotic lesions larger than 2 cm in maximal diameter, the final defect could exceed 3 or 4 cm in size due to the requirement for marginal resection until bleeding bone appears; in such cases a flap reconstruction may be applied.[28]

With the staging system presented, every stage except stage 0 takes account of the presence or absence of a mucosa or skin defect. The situation in which bone exposure occurs in combination with a mucosa defect or skin fistula is easily recognized and accepted. However, the existence of a status in which necrotic bone or a pathological fracture is found on radiological imaging but where the overlying mucosa and skin are intact is less recognized. Previous studies have confirmed that bone necrosis induced by radiation starts from the central bone with the disappearance of spongiosa, and gradually extends to the cortex bone.[18] This pattern of bone erosion may lead to radiological evidence of necrotic bone, or even pathological fracture, in the presence of an intact overlying mucosa. This rare subtype, observed at every stage, confirms the discovery of stage I patients in the study of Store and Boysen.[19]

The classification presented herein is the first in which the bone and soft tissue have been classified separately and the results then combined; this is similar to the method used for the Union for International Cancer Control (UICC) staging system. The final stage is generated from the different 'B' (bone) and 'S' (soft tissue) classifications, which makes the stages more coherent and convenient. In addition, the different 'S' classifications make an important contribution to the selection of the treatment and subsequent reconstruction.

Before distinct changes are discernible on radiography, the bone mineral must be substantially reduced and an extensive area may be involved.[29] Some have reported that mineral loss must reach 30–50% before a clear judgement can be made.[30] The situation in which bone mineral loss is less than 30% should really be defined as stage 0, but this is difficult to see on radiological imaging, thus a lower number of patients may be diagnosed at this stage. Store and Boysen[19] suggested that stage 0 should be described as a transient stage that may appear shortly after radiation therapy and from which spontaneous recovery may occur. In the classification presented herein, stage 0 relates to the patient without radiological findings who suffers from ORNM-related symptoms (mild pain $n = 5$, moderate pain $n = 3$) (bone exposure in two patients).

A total of eight patients at stage 0 received conservative therapy. The disease resolved in five of these patients, remained stable in one, and two patients progressed to stage I, proving that stage 0 is a precursor stage of stage I. Due to the retrospective nature of this study, data on the time span over which stage 0 developed into stage I were not available. Store and Boysen[19] defined their stage 0 as exposed bone in the oral cavity without evidence on radiography, which is similar to the definition of stage 0 in the study by Karagozoglu et al.[16] These staging systems have two limitations: (1) how to define the exposed bone if it is vital without mineral loss, and (2) how to categorize a situation in which there is bone mineral loss of less than 30% with an intact overlying mucosa. The classification of stage 0 presented here appears more reasonable than that of Store and Boysen as is covers the two categories mentioned above and takes into account evidence of bone-related discomfort, because it is impossible to define patients without taking into account the radiological changes and clinical symptoms. We believe that most stage 0 patients are missed because of the lack of symptoms observed at this stage.

The treatment of ORNM consists of surgical resection and conservative therapy, the latter comprising antibiotics, the application of HBO, local wound care, and the promotion of dental hygiene. HBO was applied in our institution 20 years ago, but this therapy was abandoned due to the lack of significant benefit and the high cost. To preserve the structure and function of the mandible, the surgical option should begin with removal of a small sequester, followed by sequestrectomy, segmental resection, partial resection, and finally a hemimandibulectomy. With regard to reconstruction, vascularized flaps should be considered based on the size of the defect after resection.[3,31] Nevertheless, the boundaries between conservative therapy and surgical resection are still in debate.

In a study by Santamaria et al.,[32] conservative therapy was performed in all patients, regardless of the disease severity, in an attempt to hinder or reverse the progression of ORNJ; however, about

70–83% of patients required further surgical resection after this method of treatment. We hold the view that surgical resection, including sequestrectomy, marginal or segmental resection, and even hemimandibulectomy, should be performed in patients with radiological signs of necrotic bone. This is in accordance with the concept that conservative therapy has only a temporary effect and that surgical debridement should be the principal method of treatment for ORNJ when bone necrosis is present.[33] On the one hand, devitalized bone will not recover with the conservative method; on the other, the margin of necrotic bone may be greater than expected because of its extension along the course of an obliterated blood supply.[26]

In the present study, conservative therapy was provided for all stage 0 patients. For stage I cases, the first option was sequestrectomy, and only two patients progressed to stage II, indicating that sequestrectomy is sufficient in most cases. Reconstruction was not necessary in stage I patients because of the small size of the defects after debridement of lesions <2 cm. The approach to ORNM with a maximal diameter >2 cm was surgical resection (marginal or segmental). Marginal resection was applied to those lesions close to the alveolar bone and where there was sufficient healthy bone after debridement to prevent fracture of the mandible. In the case of more extensive lesions, a segmental resection was considered an ideal option. The surgical margin was determined through preoperative CT or magnetic resonance imaging, combined with the appearance of bleeding bone during surgery. Whether a reconstruction should be performed was determined by the general condition of the patient, the volume of the defect, and the presence of recipient vessels in the irradiated area.[34] For those patients who underwent marginal resection, reconstructions were not necessary.

Reconstruction of the defect (especially in the mandibular body) after segmental resection is essential to improve function and aesthetics. Vascularized osteocutaneous flaps, such as iliac crest, fibula, and scapula flaps, are the first choice for the reconstruction of ORNM because of their bony structure and vascularized soft tissue, the latter being very important for the revitalization of injured tissues. The aim of the bone graft is to: (1) restore the continuity of bone, (2) rebuild the alveolar height, (3) prevent the face from collapsing, and (4) provide sufficient bone for further dental rehabilitation.[35] In addition, the soft tissue in the osteocutaneous flap will provide healthy, non-irradiated tissue to cover the transplanted bone, as well as providing an adequate blood supply to the recipient site.[28] For more complicated cases with through-and-through fistulas, the goal of reconstruction is to provide continuity and intraoral and external resurfacing. An osteocutaneous flap combined with a fasciocutaneous flap is often the ideal choice for the reconstruction of such bony and soft tissue defects. Intraoral coverage is obtained with the skin paddle of the osteocutaneous flap and external resurfacing is restored with the fasciocutaneous flap.[36] In addition, a double skin paddle fibula osteocutaneous flap and anterolateral thigh flap could be used as alternative flaps for reconstruction.[37,38]

In the present study, segmental resection was the only option for the patients with a bone fracture, and subsequent reconstruction was similar to that for stage II patients. The proposed staging system aims to evaluate the severity of ORNM, and we hold the view that the assessment of the extent of bone destruction is the best way to grade the ORNM. On this basis, the therapeutic method applied to stage II and III patients was formulated according to the spectrum of necrotic bone, resulting in similar treatments being used for these two different stages. However, this staging system does show the different clinical severity of ORNM. In patients who are not suitable for a bone tissue graft, a soft tissue flap can be used to fill the defect following segmental resection. In extreme cases where microvascular reconstruction cannot be performed, surgical resection without tissue transfer is also an option.

Thorough debridement of the necrotic bone was performed in all patients in stage I, II, and III, and soft tissue defects were treated successfully with the use of various flaps. Nevertheless, the mechanism of progression of ORNM remains a mystery and challenge for the surgeon, even though several hypotheses regarding its pathogenesis have been proposed, such as 'hypoxia, hypocellularity, and hypovascularity' and radiation-induced fibrosis. Disease progression appears to have no relation to inadequate resection (residual areas of necrosis at the specimen margin).[39] All of these may explain the phenomenon by which the outcomes of ORNM of different stages have no obvious diversity following various treatments.

In conclusion, the management of osteoradionecrosis remains a huge challenge for the oral and maxillofacial surgeon. A detailed classification of patients with different degrees of disease severity may facilitate the selection of appropriate treatments. The new staging system presented herein appears suitable for application in our institution; however it needs to be tested further in a prospective study or by peer evaluation.

Funding

National Natural Science Foundation of China (NSFC: 81271112); Development Foundation of Shanghai Municipal Human Resources and Social Security Bureau (201312); SMC Rising Star (A) Scholar of Shanghai Jiao Tong University.

Competing interests

No competing interests.

Ethical approval

This study did not involve human subjects.

Patient consent

Not required.

References

1. Regaud C. Sur la necrosis des os attente par un processus cancereux et traits par les radiations. *Compt Rend Soc Biol* 1922;**87**:427.
2. Marx RE. Osteoradionecrosis: a new concept of its pathophysiology. *J Oral Maxillofac Surg* 1983;**41**:283–8.
3. Morton ME. Osteoradionecrosis: a study of the incidence in the North West of England. *Br J Oral Maxillofac Surg* 1986;**24**:323–31.
4. Epstein JB, Wong FL, Stevenson-Moore P. Osteoradionecrosis: clinical experience and a proposal for classification. *J Oral Maxillofac Surg* 1987;**45**:104–10.
5. Marx RE. A new concept in the treatment of osteoradionecrosis. *J Oral Maxillofac Surg* 1983;**41**:351–7.
6. Annane D, Depondt J, Aubert P, Villart M, Géhanno P, Gajdos P, et al. Hyperbaric oxygen therapy for radionecrosis of the jaw: a randomized, placebo-controlled, double-blind trial from the ORN 96 study group. *J Clin Oncol* 2004;**22**:4893–900.
7. Bessereau J, Annane D. Treatment of osteoradionecrosis of the jaw: the case against the use of hyperbaric oxygen. *J Oral Maxillofac Surg* 2010;**68**:1907–10.
8. D'Souza J, Goru J, Goru S, Brown J, Vaughan ED, Rogers SN. The influence of hyperbaric oxygen on the outcome of patients treated for osteoradionecrosis: 8 year study. *Int J Oral Maxillofac Surg* 2007;**36**:783–7.

9. Maier A, Gaggl A, Klemen H, Santler G, Anegg U, Fell B, et al. Review of severe osteoradionecrosis treated by surgery alone or surgery with postoperative hyperbaric oxygenation. *Br J Oral Maxillofac Surg* 2000;**38**:173–6.
10. Tsai CJ, Hofstede TM, Sturgis EM, Garden AS, Lindberg ME, Wei Q, et al. Osteoradionecrosis and radiation dose to the mandible in patients with oropharyngeal cancer. *Int J Radiat Oncol Biol Phys* 2013;**85**:415–20.
11. Reuther T, Schuster T, Mende U, Kübler A. Osteoradionecrosis of the jaws as a side effect of radiotherapy of head and neck tumor patients—a report of a 30 year retrospective review. *Int J Oral Maxillofac Surg* 2003;**32**:289–95.
12. Chrcanovic BR, Reher P, Sousa AA, Harris M. Osteoradionecrosis of the jaws—a current overview—part 1: Physiopathology and risk and predisposing factors. *Oral Maxillofac Surg* 2010;**14**:3–16.
13. Delanian S, Lefaix JL. The radiation-induced fibroatrophic process: therapeutic perspective via the antioxidant pathway. *Radiother Oncol* 2004;**73**:119–31.
14. Lyons A, Osher J, Warner E, Kumar R, Brennan PA. Osteoradionecrosis—a review of current concepts in defining the extent of the disease and a new classification proposal. *Br J Oral Maxillofac Surg* 2014;**52**:392–5.
15. Schwartz HC, Kagan AR. Osteoradionecrosis of the mandible: scientific basis for clinical staging. *Am J Clin Oncol* 2002;**25**:168–71.
16. Karagozoglu KH, Dekker HA, Rietveld D, de Bree R, Schulten EA, Kantola S, et al. Proposal for a new staging system for osteoradionecrosis of the mandible. *Med Oral Patol Oral Cir Bucal* 2014;**19**:e433–7.
17. Notani K, Yamazaki Y, Kitada H, Sakakibara N, Fukuda H, Omori K, et al. Management of mandibular osteoradionecrosis corresponding to the severity of osteoradionecrosis and the method of radiotherapy. *Head Neck* 2003;**25**:181–6.
18. Store G, Larheim TA. Mandibular osteoradionecrosis: a comparison of computed tomography with panoramic radiography. *Dento Maxillofac Radiol* 1999;**28**:295–300.
19. Store G, Boysen M. Mandibular osteoradionecrosis: clinical behaviour and diagnostic aspects. *Clin Otolaryngol Allied Sci* 2000;**25**:378–84.
20. van Merkesteyn JP, Balm AJ, Bakker DJ, Borgmeyer-Hoelen AM. Hyperbaric oxygen treatment of osteoradionecrosis of the mandible with repeated pathologic fracture. Report of a case. *Oral Surg Oral Med Oral Pathol* 1994;**77**:461–4.
21. Cheng SJ, Lee JJ, Ting LL, Tseng IY, Chang HH, Chen HM, et al. A clinical staging system and treatment guidelines for maxillary osteoradionecrosis in irradiated nasopharyngeal carcinoma patients. *Int J Radiat Oncol Biol Phys* 2006;**64**:90–7.
22. Nabil S, Ramli R. The use of buccal fat pad flap in the treatment of osteoradionecrosis. *Int J Oral Maxillofac Surg* 2012;**41**:1422–6.
23. Armin BB, Hokugo A, Nishimura I, Tamplen M, Beumer 3rd J, Steinberg ML, et al. Brachytherapy-mediated bone damage in a rat model investigating maxillary osteoradionecrosis. *Arch Otolaryngol Head Neck Surg* 2012;**138**:167–71.
24. Clayman L. Clinical controversies in oral and maxillofacial surgery: part two. Management of dental extractions in irradiated jaws: a protocol without hyperbaric oxygen therapy. *J Oral Maxillofac Surg* 1997;**55**:275–81.
25. Glanzmann C, Grätz KW. Radionecrosis of the mandibula: a retrospective analysis of the incidence and risk factors. *Radiother Oncol* 1995;**36**:94–100.
26. Coffin F. The incidence and management of osteoradionecrosis of the jaws following head and neck radiotherapy. *Br J Radiol* 1983;**56**:851–7.
27. Hutchinson IL. Complication of radiotherapy in the head and neck: an orofacial surgeon's view. In: Tobias JS, Thomas PR, editors. *Current radiation oncology*. London: Hodder Arnold; 1995. p. 144–77.
28. Buchbinder D, St Hilaire H. The use of free tissue transfer in advanced osteoradionecrosis of the mandible. *J Oral Maxillofac Surg* 2006;**64**:961–4.
29. Epstein JB, Rea G, Wone FL, Spinelli J, Stevenson-Moore P. Osteonecrosis: study of the relationship of dental extraction in patients receiving radiotherapy. *Head Neck Surg* 1987;**10**:48–54.
30. Malska WI. Microdensitometric analysis of the influence of X-irradiation on mature bone in humans. *Acta Med Pol* 1971;**12**:357–8.
31. Chrcanovic BR, Reher P, Sousa AA, Harris M. Osteoradionecrosis of the jaws—a current overview—part 2: dental management and therapeutic options for treatment. *Oral Maxillofac Surg* 2010;**14**:81–95.
32. Santamaria E, Wei FC, Chen HC. Fibula osteoseptocutaneous flap for reconstruction of osteoradionecrosis of the mandible. *Plast Reconstr Surg* 1998;**101**:921–9.
33. Coskunfirat OK, Wei FC, Huang WC, Cheng MH, Yang WG, Chang YM. Microvascular free tissue transfer for treatment of osteoradionecrosis of the maxilla. *Plast Reconstr Surg* 2005;**115**:54–60.
34. Hao SP, Chen HC, Wei FC, Chen CY, Yeh AR, Su JL. Systematic management of osteoradionecrosis in the head and neck. *Laryngoscope* 1999;**109**:1324–7.
35. Marx RE, Ames JR. The use of hyperbaric oxygen therapy in bony reconstruction of the irradiated and tissue deficient patients. *J Oral Maxillofac Surg* 1982;**40**:412–20.
36. Baumann DP, Yu P, Hanasono MM, Skoracki RJ. Free flap reconstruction of osteoradionecrosis of the mandible: a 10-year review and defect classification. *Head Neck* 2011;**33**:800–7.
37. Jones NF, Vögelin E, Markowitz BL, Watson JP. Reconstruction of composite through-and-through mandibular defects with a double-skin paddle fibular osteocutaneous flap. *Plast Reconstr Surg* 2003;**112**:758–65.
38. Yu P. One-stage reconstruction of complex pharyngoesophageal, tracheal, and anterior neck defects. *Plast Reconstr Surg* 2005;**116**:949–56.
39. Zaghi S, Miller M, Blackwell K, Palla B, Lai C, Nabili V. Analysis of surgical margins in cases of mandibular osteoradionecrosis that progress despite extensive mandible resection and free tissue transfer. *Am J Otolaryngol* 2012;**33**:576–80.

Address:
Zhiyuan Zhang
Department of Oral Maxillofacial and Head and Neck Oncology
Shanghai Ninth People's Hospital Affiliated to Shanghai Jiao Tong University School of Medicine
Zhi-zao-ju Road
No. 639
Shanghai 200011
China